Faculteit lichamelijke opvoeding en kinesitherapie

Module Onderzoek en Behandeling IIIB
Physiopedia

Cervicogenic Headache

Academiejaar 2016-2017
Glenn Elsocht, Tim Delaunaij, Mathieu Van Durme
Evelynn Van Hautegem

Cervicogenic Headache

Contents
[hide]

Search strategy

Information concerning 'cervicogenic headache' was collected by using article databases, such as Pubmed, Web of Knowledge and ScienceDirect. The key words used are: cervical spine, headache, treatment/therapy, cervicogenic headache. Each key word gives of articles but the most relevant were: cervicogenic headache and therapy/ treatment. We also have consulted books to get information on CHP.

Definition/Description

The International Headache Society (IHS 2013) has validated cervicogenic headache as a secondary headache, which means headache caused by a disorder of the cervical spine and its component bony, disc and/or soft tissue elements, usually but not invariably accompanied by neck pain. [(4)]

Diagnostic criteria: [(4)]

A. Any headache fulfilling criterion C
B. Clinical, laboratory and/or imaging evidence of a disorder or lesion within the cervical spine or soft tissues of the neck, known to be able to cause headache
C. Evidence of causation demonstrated by at least two of the following:
    1. headache has developed in temporal relation to the onset of the cervical disorder or appearance of the lesion
    2. headache has significantly improved or resolved in parallel with improvement in or resolution of the cervical disorder or lesion
    3. cervical range of motion is reduced and headache is made significantly worse by

provocative manœuvres
4. headache is abolished following diagnostic blockade of a cervical structure or its nerve supply

D. Not better accounted for by another ICHD-3 diagnosis.

It is a chronic headache that arises from the atlanto-occipital and upper cervical joints and perceived in one or more regions of the head and/or face.[1] These occur due to a neck disorder or lesion and feature the converging of trigeminal and cervical afferents in the trigeminocervical nucleus within the upper cervical spinal cord.[2] By definition the headache should be abolished following a diagnostic blockade of a cervical structure or its nerve supply.[3]

Figure 1: Cervicogenic Headache

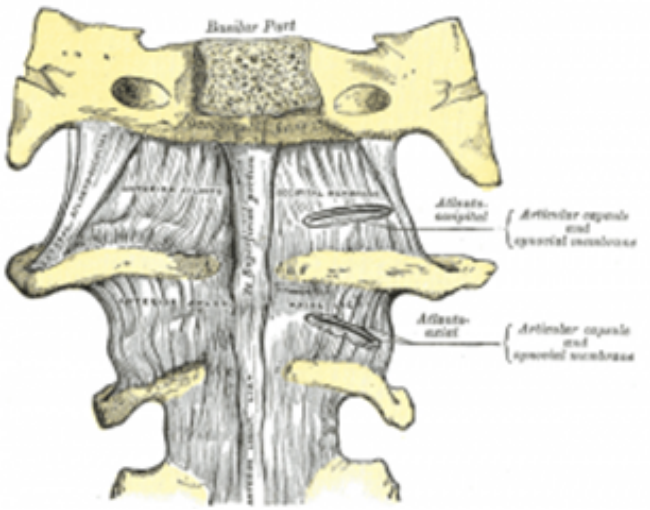

Figure 2: Upper Cervical Spine

Clinical relevant anatomy

The anatomic basis for cervicogenic headache lies in the relationship between afferents of the upper three cervical nerves and the afferents of the trigeminal nerve [2]. Any structure innervated by the C1–C3 spinal nerves could be the source of cervicogenic headache. The other possible sources for cervicogenic headache could be the dorsal roots from C1 through C7, the intervertebral disks down to the C7 level, the zygapophyseal joints from C2-3 to C6-7, and especially the greater and lesser occipital nerve, the third occipital nerve, and the major auricular nerve. This suggests, but remains speculative, that cervicogenic headache may be caused by structures in the mid- and lower cervical spine.[34]

Articulations

The cervical spine consists of 7 vertebrae, C1 to C7. The cervical nerves from C1 to C8. The first two vertebrae have a unique shape and function.[5] The upper vertebrae supports the skull, articulates superiorly with the occiput (the atlanto-occipital joint) and is named the atlas (C1). This joint is responsible for 50% of flexion and extension.[6] The design of the atlas allows forward and backward movement of the head. Among the atlas is the axis (C2) that allows rotation.[5] The atlantoaxial joint is responsible for 50% of all cervical rotation. Both form the upper cervical spine. The 5 cervical vertebrae that make up the lower cervical spine, C3-C7, are similar to each other but very different from C1 and C2.[26]

http://www.youtube.com/watch?v=KdFUfVFEb4U

Intervertebral discs are located between the vertebral bodies of C2-C7. These disks are composed of 4 parts: the nucleus pulposus in the middle, the annulus fibrosis surrounding the nucleus, and 2 end plates that are attached to the adjacent vertebral bodies. They serve as force dissipators, transmitting compressive loads throughout a range of motion. The disks are thicker anteriorly and therefore contribute to normal cervical lordosis. The intervertebral disks are involved in cervical spine motion, stability, and weight-bearing.[7]

Muscles

The most important muscles that are totally or partially located cervical are:[8]

- Erector spinae, upper Extension, rotation C1–T1
- Longus capitis Flexion C1–C3
- Longus colli Flexion C2–C6
- Rectus capitis anterior Flexion C1–C2
- Rectus capitis lateral Flexion C1–C2
- Scalenes Flexion, rotation C4–C8
- Semispinalis capitis Extension, rotation C1–T1
- Semispinalis cervicis Extension, rotation C1–T1
- Splenius capitis Extension, rotation C1–C8
- Splenius cervicis Extension, rotation C1–C8
- Sternocleidomastoid Flexion, rotation C2, XI
- Trapezius, upper Extension, rotation C3-C4
- Levator scapula Elevatie scapula C3-C5
- Rhomboideus minor Retrotractie scapula + fixation C4-C5

Cervicogenic headache pain has been mostly related to joint, disk, and ligament pain from the upper cervical spine. However, the upper cervical spine also receives afferent inputs from muscles. The role of referred pain to the head elicited by muscle tissues has received particular interest in recent year [30,31]. A TrP is usually defined as a hyperirritable spot within a taut band of a skeletal muscle that elicits a referred pain upon examination. From a clinical point of view, TrPs can be classified as active or latent. Active TrPs are those which local and referred pain reproduces the pain symptoms, for example, reproduce the headache pattern.(30,31)

Myofascial pain and its relation to so-called ‘trigger points’ is controversial. It has been difficult consistently to demonstrate supposed trigger points, and response to treatment varies. (IHS, Classification? 2013 Cephalagia, p176).

In a study by Huber et al., results demonstrated positive correlations between increase in rest-EMG amplitudes and high VAS scores for cervicogenic headache intensity and increased numbers of TrP were also found [31].

A pilot RCT divided diagnosed cervicogenic headache patients with active TrP in the sternocleidiomastoid muscles into two groups. Patients receiving TrP therapy showed more decrease in neck pain and headache, as well as higher improvements in AROM compared to the group receiving simulated TrP therapy. Effect sizes between both groups were all > 0.84 [30].

Ligaments

The most important ligaments that are totally or partially located cervical are:[8][7]

- Alar Axis-skull head rotation & lateral flexion
- Anterior atlantoaxial Axis & atlas extension
- Posterior atlantoaxial Axis & atlas flexion
- Ligamentum nuchae cervical flexion
- Anterior longitudinal Axis-sacrum Extension
- Posterior Longitudinal Axis-sacrum Flexion
- Ligament flavum Axis-sacrum flexion

Nerves

The mechanism which is responsible for the pain consists of a merger of the spinal nerves C1, C2 and C3, and a branch of the 5th cranial nerve, the trigeminal nerve. This merger of nerves makes it possible that upper cervical pain radiate to regions of the head which are innervated by the cervical nerve (auricular and occipital). The merger with the trigeminal afferents allows the pain to radiate to the parietal, frontal and orbital regions.[2][9][10] The trigeminocervical nucleus is a region of the upper cervical spinal cord where sensory nerve fibers in the descending tract of the trigeminal nerve converge with sensory fibers from the upper cervical roots. This convergence of nociceptive pathways allows for the referral of pain signals from the neck to the trigeminal sensory receptive fields of the face and head as well as activation of the trigeminovascular neuroinflammatory cascade. Also relevant to this condition is the convergence of sensorimotor fibers of the spinal accessory nerve (CN XI) and upper cervical nerve roots, which ultimately converge with the descending tract of the trigeminal nerve. These connections may be the basis for the well-recognized patterns of referred pain from the trapezius and sternocleidomastoid muscles to the face and head [9].

Epidemiology/Etiology

Of all chronic headaches, CEH is one of the more common types of headache. The incidence of cervicogenic headache has been estimated to be 14-18%,[11] though in a recent population-based study a 2.2% prevalence was found[12]. These numbers vary because not all studies respect the HIS classification guidelines for diagnosis of CEH. The presence of cervicgenic headache needs to be confimed by nerve block diagnosis (IHS, Classification, 2013, p133). Women have been reported to be affected four times more frequently than men(35), although some research about prevalence between the sexes is contradictory. It is important we can distinguish cervicogenic headache from the other headaches like migraine, tension type headache. The term cervicogenic headache (CGH) was coined almost 3 decades ago, and the general condition of pain located in the head but originating in the cervical spine was described over 100 years ago. It is similar to other non-specific spinal conditions in its relative lack of high level evidence regarding pathoanatomical etiology. Since there is no objective test set for diffinitive diagnosis of CGH, the condition is ruled in, and treatment chosen, based on the patient's subjective report of pain patterns. [13]

There is some evidence that multiple structures in the upper cervical spine can be the source that is referring pain into the head. The implicated structures are generally centered around C1, C2, and C3 spinal levels. This may include the joints, disc, ligaments, and musculature.[14] The lower cervical spine may play an indirect role in pain production if dysfunctional, but there is no evidence of a direct referral pattern.[14] Through controlled nerve blocking of various structures in the cervical spine, it appears that the zygoapophyseal joints, especially those of C2/C3, are the most common sources of CGH pain. This finding is even more common in patients with a history of whiplash. [14]

Dysfunction of the neck and shoulder girdle muscles can be one of the main etiological factor responsible for CEH.[31]

Patients with cervicogenic headache demonstrated declines in the quality of life comparable to migraine-patients and patients with tension-type headache, with even lower scores for physical functioning. [40]

Clinical Presentation

Challenging to diagnose clinically, but often includes:

- Unilateral "ram's horn" or unilateral dominant headache[15] (Excluding those with bilateral headache or symptoms that typify migrane headaches).
- Exacerbated by neck movement or posture[15]
- Tenderness of the upper 3 cervical spine joints[15]
- Association with neck pain or dysfunction[16]
- Definitive diagnosis made through selective nerve blocking through injection of specific sites[14]
- Compared to migraine headache and control groups, cervicogenic headache group patients tend to have increased tightness and trigger points in upper trapezius, levator scapulae, scales and suboccipital extensors[1], splenius capitis and sternocleidomastoideus [30,31]
- Weakness in the deep neck flexors[15][17][18]
- Increased activity in the superficial flexors
- Atrophy in the suboccipital extensors and so the deep muscle sleeve which is important for active support of the cervical segments becomes impaired
- upper trapezius, sternocleidomastoid, scalenes, levator scapulae, pectoralis major and minor, and short sub-occipital extensors have been implicated[15][17][19]
- Trigger points have been reported to be present in patients with tension type headache, migraine, and cluster headache [(39)]. In addition, active TrPs have been also related to neck pain, a common symptom experienced by individuals with cervicogenic headaches. [30,31]

Differential Diagnosis

It is important to differentiate from serious pathology such as:

- Cervical Arterial Dysfunction
- Intracranial Pathology
- Cervical Instability

It is also important to differentiate from other types of headache **(figure 3, 4, 5):**

Type	*Location*	*Intensity*	*Frequency*	*Duration*	*Additional Symptoms*
Cluster	Unilateral: (orbital, supraorbital, temporal)	Severe	1x every other day - > 8x day	15-180 minutes	Associated with ipsilateral: conjunctival injection, lacrimation, nasal congestion, rhinorrhoea, forehead and facial sweating, miosis, ptosis, eyelid edema. Restlessness or agitation.
Tension	Bilateral	Mild-Moderate	>15day/mo, >3 mo	Hours-continuous	Pressing, tightening <1 of photophobia, phonophobia or mild nausea
Migraine without aura	Unilateral: Frontotemporal in adults, Occipital in children	Moderate-Severe	>14 days/month	4-72 hours	Flickering lights/spots in vision, pulsating quality, nausea, photophobia, phonophobia

figure 3: differential diagnosis

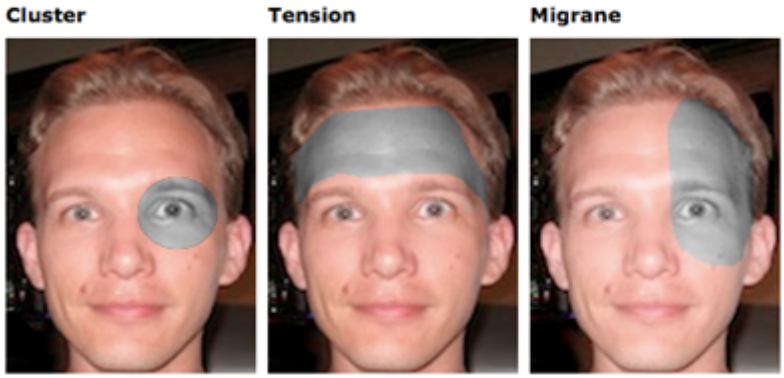

Figure 4: differential diagnosis: localisation headache

DIFFERENTIAL DIAGNOSIS OF HEADACHE			
Clinical features	**Cervicogenic headache**	**Migraine**	**Tension-type headache**
Female:Male	50:50	75:25	60:40
Lateralization	Unilateral without sideshift	60% unilateral with sideshift	Diffuse bilateral
Location	Occipital to frontoparietal and orbital	Frontal, periorbital, temporal	Diffuse
Frequency	Chronic, episodic	1-4 per month	1-30 per month
Severity	Moderate-severe	Moderate/Severe	Mild/moderate
Duration	1 hour to weeks	4-72 h	Days to weeks
Pain character	Non-throbbing, and non-lancinating, pain usually starts in the neck	Throbbing, pulsating	Dull
Triggers	Neck movement, and postures, limited ROM, pressure over C0-C3	Multiple, neck movement not typical	Multiple, neck movement not typical
Associated Symptoms	Usually absent or similar to migraine but milder, decreased ROM	Nausea, vomiting, visual changes, phonophobia, photophobia	Occasionally decreased appetite, phonophobia or photophobia

Figure 5: differential diagnosis

Cybex Dynamometry

Another possibility to distinguish cervicogenic headache from migraine and tension headache is the use of a Cybex dynamometry.[20] Testing using Cybex dynamometry has shown that the ranges of cervical flexion, extension and rotation are significantly less in patients with cervicogenic than in patients with migraine and tension type headache ($p < 0.001$). Investigators also found that tenderness is a factor that varies between patients with CGH and patients with migraine or tension type headaches. Bovim measured pressure pain thresholds at ten points on the head and suboccipital region in patients with CGH, tension type headache and migraine.[21] Lower scores were found in patient with cervicogenic headaches than without.

Passive physiological intervertebral movements (PPIVMs) Sn= 0.05 , Sp = 0.99

A good reliabel differential test (in combination with CFRT) is the Passive Physiological Intervertebral Movements (PPIVMs) . this is most often used in assessment capacity rather than as a treatment therapy. PPIVMs are used to determine a rango of properties of spinal movement that will guide the use of manual therapy techniques. PPIVMs test the movement available at the spinal level identified by application of a passive physiological motion and palpating between adjacent spinous process or articular facet. While the therapist passively moves the spine they can note the range of motion, any muscle spasm or provocation of pain. They can confirm any restriction of motion seen in active movement and can also identify hypermobility. Additionally the spine can be taken to the end of range and there the therapist can apply over pressure to assess the end-feel of the movement. In this way PPIVMs can help the therapist to identify location, nature, severity an d irritability of symptoms.[33]

https://www.youtube.com/watch?v=hr66Q7rmz2o

Diagnostic Procedures

Here are no diagnostic imaging techniques of the cervical spine and associated structures that can determine the exact source of pain. Therefore, diagnosis and treatment are based on the major accepted criteria of clinical presentation and the use of diagnostic nerve blocks to identify the source of the pain generator before considering further interventional or neuroablative treatment. This suggests that consistent reproducible anatomic and neurophysiologic pathways exist for the reproduction of typical clinical pain patterns and the ability of neuroblockade to consistently interrupt these pain pathways. (37)

Accurate diagnosis of CGH is difficult due to the heterogeneity of its presentation and the multiple pain generators within the trigeminocervical nucleus-upper cervical nerve convergence. It is currently not possible to determine whether the pain generator is somatic referred or radicular-type pain, other than to attempt blockade of cervical nerve root, facet joint, atlantoaxial, myofascial trigger point, or occipital nerve steroid injection. Each cervical procedure carries potential risks. CESI with an interlaminar needle approach at C7-T1 or C6-7 epidural space is relatively safe compared to other cervical procedures. (38)

Outcomes measures

- Neck Disability Index
- Headache Disability Index
- The Northwick Park Questionnaire
- Neck Pain and Disability Scale
- Numeric Pain Rating Scale
- Pain visual analog scale

Examination

Diagnostic Criteria (as described by the IHS)[3]:

A. Pain, referred from a source in the neck and perceived in one or more regions of the head and/or face, fulfilling criteria C and D
B. Clinical, laboratory and/or imaging evidence of a disorder or lesion within the cervical spine or soft tissues of the neck known to be, or generally accepted as, a valid cause of headache
C. Evidence that the pain can be attributed to the neck disorder or lesion based on at least one of the following:
    a. demonstration of clinical signs that implicate a source of pain in the neck
    b. abolition of headache following diagnostic blockade of a cervical structure or its nerve supply using placebo- or other adequate controls
D. Pain resolves within 3 months after successful treatment of the causative disorder or lesion

Notes:

1. Tumours, fractures, infections and rheumatoid arthritis of the upper cervical spine have not been validated formally as causes of headache, but are nevertheless accepted as valid causes when demonstrated to be so in individual cases. Cervical spondylosis and osteochondritis are NOT accepted as valid causes fulfilling criterion B. When myofascial

tender spots are the cause, the headache should be coded under Tension-type headache.

2. Clinical signs acceptable for criterion C1 must have demonstrated reliability and validity. The future task is the identification of such reliable and valid operational tests. Clinical features such as neck pain, focal neck tenderness, history of neck trauma, mechanical exacerbation of pain, unilaterality, coexisting shoulder pain, reduced range of motion in the neck, nuchal onset, nausea, vomiting, photophobia etc are not unique to cervicogenic headache. These may be features of cervicogenic headache, but they do not define the relationship between the disorder and the source of the headache.
3. Abolition of headache means complete relief of headache, indicated by a score of zero on a visual analogue scale (VAS). Nevertheless, acceptable as fulfilling criterion C2 is ≥90% reduction in pain to a level of <5 on a 100-point VAS

Flexion-Rotation Test Sn = 0.91, Sp = 0.90[19]

The inverse relationship between headache severity of CGH and ROM towards the most restricted side for the Cervical Flexion-Rotation Test (FRT) was statistically significant for all patients with cervicogenic headaches.[19] The patient should feel no pain at the time of the test. During this test, the neck of the patient is passively held in end range flexion. The therapist rotates the neck to each side until they feel resistance or until the patient says they are in pain. At this end point, the therapist makes a visual estimate of the rotation range and says on which side the FRT was positive or negative. The test was positive when the estimated range was reduced by more than 10° from the anticipated normal range (44°).

https://www.youtube.com/watch?feature=player_embedded&v=YbWu_j95OTU

"Red flags"

1. Sudden onset of a new severe headache;
2. A worsening pattern of a pre-existing headache in the absence of obvious predisposing factors;
3. Headache associated with fever, neck stiff ness, skin rash, and with a history of cancer, HIV, or other systemic illness;
4. Headache associated with focal neurologic signs other than typical aura;
5. Moderate or severe headache triggered by cough, exertion, or bearing down; and
6. New onset of a headache during or following pregnancy.
7. Headache onset after trauma.
8. Persistent and/or progressive headache.
9. Focal signs or symptoms.
10. Headache triggered by changes in posture.
11. New headache in patients over 50 years of age

Patients with one or more red flags should be referred for an immediate medical consultation and further investigation.[19] (32)

Medical Management

The failure to conclusively demonstrate a specific disease or dysfunction of the neck in relation to cervicogenic headache has been an impediment to specific treatment for individuals with the diagnosis.

Cervical epidural steroid injections: Indicated for multilevel disc or spine degeneration
CESI is considered by many interventional pain management specialists to be a reasonable option for patients who have failed conservative treatments.(38)

Nerve Blocks: Disrupting the cascade of signals leading to sensitization to central mechanisms via:

- Nerve blocks
- Trigger point injections
- Radiofrequency thermal neurolysis

Current best evidence suggests that there is not sufficient evidence meeting the EBM criteria to support the use of RF facet denervation for cervicogenic headaches.[22]

Surgical interventions: Often only provide temporary relief with the possibility of longer intensification of pain.[1] Procedures Include:

- Neurotomy
- Dorsal rhizotomy
- Microvascular decompression of nerve roots

Other Medications:

- Tricyclic antidepressants - Used at lower dosage than required for pts diagnosed with depression
- Muscle relaxants - Related to the CNS, may be beneficial, evidence is still pending
- Botulinum toxin - A neurotoxin injected into tender muscles to reduce hypertonia

Physical Therapy Management

The preferred practice pattern for cervicogenic headache is 5 dimensional: pain control, centralization, mobility, exercise and conditiond and headache [23]. Impaired Motor Function and Sensory Integrity Associated with Nonprogressive Disorders of the Central Nervous System-Acquired in Adolescence or Adulthood. Goodman states that "Although this type of headache is responsive to therapy oriented at treating the soft tissue restrictions, the method of examination, assessment, and treatment needs to be specific to the neck and occiput."[1]

Treatment

- Mobility: Cervical spine manipulation or mobilization[24]
- Strengthening exercises[24]

- Deep neck flexors
- Upper quarter muscles
  - Thoracic spine thrust manipulation & exercise[25]
  - C1-C2 Self-sustained Natural Apophyseal Glide (SNAG)[26]
- shown to be effective for reducing cervicogenic headache symptoms

Jull et al[15] reported that a six week physiotherapy program including manual therapy and exercise interventions was an effective treatment option for reduction of cervicogenic headache symptoms and decreasing medication intake in both the short term and at one-year follow-up.

https://www.youtube.com/watch?feature=player_embedded&v=KdFUfVFEb4U
https://www.youtube.com/watch?feature=player_embedded&v=1smVSuQiQx8
https://www.youtube.com/watch?feature=player_embedded&v=Rj4Y5JGNPZs
https://www.youtube.com/watch?feature=player_embedded&v=TNb2cLsgc6c

Other Treatment Options

Thoracic Manipulation

Seated CT Manipulation
https://www.youtube.com/watch?feature=player_embedded&v=R64_I_2P2bk

Seated Mid Thoracic Manipulation
https://www.youtube.com/watch?feature=player_embedded&v=KGWGr42nKdk

Re-educating craniocervical spine flexor muscles

Deep Neck Flexor Exercises
https://www.youtube.com/watch?feature=player_embedded&v=IT8CG7NEjrY

Re-education of craniocervical flexion (CCF) movement[15] - The neck flexor muscle synergy is tested with the Cranio-cervical Flexion Test. The patient palpates the superficial flexors to avoid their inappropriate use. An emphasis on precision and control is essential.

Training the low level endurance capacity of the deep neck flexors[15] - Begins as soon as the patient can perform the CCF movement correctly. This phase tests the patient's ability to hold (approximately 10 seconds) the cranio-cervical flexion position in each stage of the test on repeated occasions. Pressure biofeedback is used to guide training. Training begins at the pressure level that the patient can achieve and hold steady with a good pattern, without dominant use or substitution by the superficial flexor muscles. The patient performs the formal exercise at least twice daily. For each pressure level, the holding time is built up to 10 seconds and 10 repetitions are performed, eventually to the desired level of 30 mm Hg.

Retraining the cervical flexors for antigravity function in sitting position[15] - The exercise is a controlled eccentric action of the flexors into cervical extension range followed by a concentric action of these muscles to return the head to the neutral upright position. The return to the upright position must be initiated by CCF, rather than a dominant action of sternocleidomastoid. The exercise is progressed by gradually increasing the range to which the head is moved into extension as control improves, and introducing isometric holds through range.

Extensors of the craniocervical spine[15]

The patient practices eccentric control of the head into flexion followed by concentric control back to the neutral position in a 4 point kneeling position to train the coordination of the deep and superficial cervical extensors. These exercises are incorporated with re-education of the scapular muscles in these positions and are commenced early in the program. The exercise is

progressed by performing alternating small ranges of craniocervical extension and flexion while maintaining the cervical spine in a neutral position. Co-contraction of the neck flexors and extensors[15]

Co-contraction of the neck flexors and extensors[15]

The co-contraction is facilitated with rotation and the exercises are introduced once the patient can activate the deep muscles. The patient uses self resisted isometric rotation in a correct upright sitting posture. They look into the palm of the hand, providing the resistance to facilitate the muscles and perform the alternating rhythmic stabilisation exercises with an emphasis on slow onset and slow release holding contractions, using resistance to match about a 10–20% effort. Retraining the strength of the superficial and deep flexor synergy[15]

Retraining the strength of the superficial and deep flexor synergy [15]

The head lift must be preceded with CCF followed by cervical flexion to just lift the head from the bed. Gravity and head load provide the resistance. Care must be taken that high load exercise is not introduced too early, as it may be provocative of symptoms.

Retraining the scapular muscles

Retraining scapular orientation in posture[15] - A correction strategy is to have the patient move the coracoids upward and the acromion backwards, which results in a slight retraction and external rotation of the scapula. The aim is to facilitate the coordinated action of all parts of trapezius and serratus anterior, allowing lower trapezius to slightly depress the medial border of the scapula, consequently lengthening (and relaxing) the levator scapulae. Once the patient learns correct scapular orientation, he repeats the correction and maintains the position regularly throughout the day so that it becomes a habit.

Training the endurance capacity of the scapular stabilisers[15] - Repeated repetitions of 10 second holds of the corrected scapular position encourages early endurance retraining. Endurance of the middle and lower trapezius muscles is also trained by performing exercise in the prone lying position against the effects of gravity.

Retraining scapular control with arm movement and load[15] - This is important when activities such as computer or deskwork aggravate pain. The patient is encouraged to maintain their newly learnt scapular position while performing small range (+/- 60 degrees) arm movements, or during, for example, work at a computer. Scapular control in association with control of cervicothoracic postural position is also trained for functional activities such as lifting and carrying.

Upper quarter strengthening exercises[17]

Figure 6: Middle Trapezius Strengthening



Figure 7: Lower Trapezius Strengthening

Adding upper quarter exercises for patients with cervical dysfunction is important in order to integrate 'global' muscles that have connections to the cervical spine through anatomical chains (most notably those connecting the axial and appendicular skeletons).

Re-education of posture[15]

Posture is an indirect measure of the functional status of the neuromuscular system.[19] Postural position is trained in sitting and is corrected from the pelvis. The second aspect of re-education of postural position is correction of scapular position. Maintenance of a correct scapular position with appropriate muscle coordination has the added benefit of inducing reciprocal relaxation in muscles such as levator scapulae, which reduces muscular pain in the area.

Sensorimotor training

Because CGHs are thought to be a dysfynction of the sensorimotor system.[17] Sensorimotor exercises include progressive exercise on unstable surfaces to promote reflexive stabilization and postural stability. Unstable surfaces such as exercise balls or foam pads can be used to add challenge to the cervical spine as well as the whole-body for stabilization exercises. These final stages of the rehabilitation program for CGH patients can be progressed toward functional activities to return the patient to full participation.

Trigger point therapy **(30: level of evidence 1B)**

This is composed of different manual approaches, for example, compression, stretching, or transverse friction massage. Pressure release over the sternocleidomastoid muscle TrP is applied and pressure is progressively applied and increased over the TrP until the finger encountered an increase in tissue resistance (tissue barrier). This pressure is maintained until the therapist sensed a relief of the taut band. At that moment, the pressure is increased again until the next increase in tissue resistance. Do this 3x/session. Stretching of the taut band muscle fibers is also important. This technique has been found to be effective for lengthening the TrP in the muscle and the associated connective tissue. The therapist apply moderate slow pressure over the TrP and slides the fingers in the opposite directions. Trigger point manual therapy is applied slowly and is performed without inducing pain to the patients.

(Myofascial) Mobility, strength, stability and postural exercices [31 level of evidence 1B]

These technics were primarily postisometric relaxation procedures (A), myofascial mobilization (B) and selected elements of McKenzie therapy (C). Exercises were mainly applied to the muscles with TrPs, showing the pathological increase in rEMG amplitude.

When relaxation of painful, tensed muscles is achieved, the next step of treatment include strengthening exercises of the same muscles. All of them are supervised by a physiotherapist. Exercises intensity shall not increase the pain sensation in the cervical spine, shoulder and girdle muscles. They aren't supposed to evoke the headache. There are isometric exercises with the gradual loading increase (D) and dynamic exercises (E). Elastic therabands are commonly used during these exercises. Additionally, the self-control exercises of the correct body posture are carried out in front of the mirror relying on the visual feedback (F).

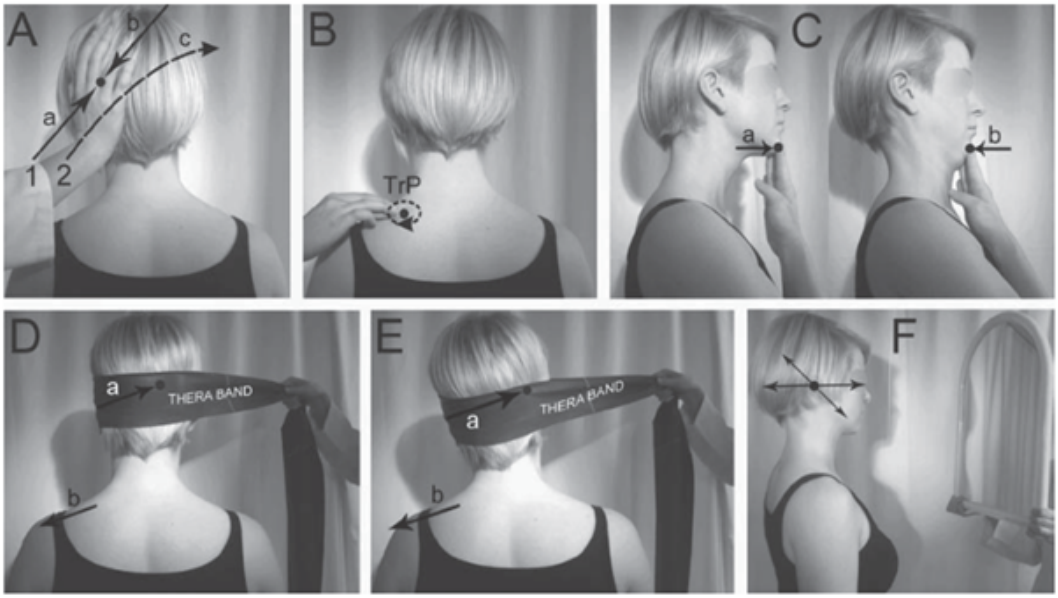

Figure 8: Photographs illustrating principles of the kinesiotherapeutic procedures applied to the patients from supervised group [31 level of evidence 1B] A-postisometric relaxation including two steps (1a-hand pressure and 1b-head counterpressure, 2-passive head movement a er 10 seconds of pressure). B-example of trigger point (TrP) myofascial mobilization in trapezius muscle using the circular pressure. C-head protraction (a) and retraction (b) according to McKenzie therapy. D-strengthening exercises using the elastic band (a-constant elastic band tension, b-trapezius muscle static contraction). E- strengthening exercises using the elastic band (a-gradual elastic band tension, b-trapezius muscle dynamic contraction). F-self-control exercises of the correct body posture (two dimensional head postural alignment with visual feedback).

Key Research

- Jull G, Stanton W. *Predictors of responsiveness to physiotherapy management of cervicogenic headache.* Cephalalgia. 2005;25:101-108.[15]
- Hall T et all. *Clinical Evaluation of Cervicogenic Headache: A Clinical Perspective.* Journal of Manual and Manipulative Therapy. 2008;16:73-80.[19]
-

Resources

- International Headache Society [(4)]
- Treatment-based classification approach to neck pain

Harrisonvaughanpt. C1-2 Rotatory HVLAT Chin-Hold Technique. Available from: http://www.youtube.com/watch?v=KdFUfVFEb4U [last accessed 24/11/12][(26)]

OptimumCareProviders. 1.2 Deep Neck Flexor - Longus Colli Strengthening Level 2. Available from: http://www.youtube.com/watch?v=1smVSuQiQx8 [last accessed 09/03/13] ([(27)]

ReligiosoPT. Supine Thoracic Thrust. Available from: http://www.youtube.com/watch?v=Rj4Y5JGNPZs[last accessed 09/03/13]|} [(28)]

TherExVids. Cervical Rotation Self Mobilization Using a Strap. Available from: http://www.youtube.com/watch?v=TNb2cLsgc6c[last accessed 09/03/13]|} [(29)]

Clinical Bottom Line

For reducing the symptoms of cervicogenic headache it's most effective to make use of physiotherapy.[15] There is evidence that manipulation/mobilization of the cervical spine, training of the deep neck flexors, training and manipulation of the upper quarter muscles. Other excercises could also work for this kind of headache.[24][25][26]

Presentations

Cervicogenic headaches: an evidence update by Mark Shepherd
https://www.youtube.com/watch?feature=player_embedded&v=t7uQjUqFyA8

Recent Related Research (from Pubmed)

http://www.ncbi.nlm.nih.gov/pmc/articles/PMC4800981/

Garcia J.D. et al., *Mobilization and Manipulation of the Cervical Spine in Patients with Cervicogenic Headache: Any Scientific Evidence?* Front Neurol. 2016; 7: 40. Published online 2016 Mar 21. Level of Evidence 1A.

References

1. ↑ 1.0 1.1 1.2 1.3 Goodman, C, Fuller, K. Pathology: Implications for the Physical Therapist. 3rd ed. St. Louis: Saunders Elsevier, 2009.
2. ↑ 2.0 2.1 Bogduk N, Govind J. *Cervicogenic headache: an assessment of the evidence on clinical diagnosis, invasive tests, and treatment.* Lancet Neurol 2009; 8: 959–68.
3. ↑ 3.0 3.1 HIS Classification ICHD-II. Cervicogenic headache [M99]. http://ihs-classification.org/en/02_klassifikation/03_teil2/11.02.01_cranial.html (accessed 13 April 2011).
4. Olesen, J., 2013. The International Classification of Headache Disorders, 3rd edition. *Cephalagia*, 33(9), pp.629–808.
6. R. E Windsor et al., cervical spine anatomy, july 2011, medscape.Level of evidence: 5
7. ↑ 8.0 8.1 R. C. Schafer, Chapiter 5: the posterior neck and cervical spine, book "Symptomatology and Differential Diagnosis" 2011. Level of evidence: 5
8. ↑ 9.0 9.1 Biondi D.*, cervicogenis headache: a review of a diagnostic process and traitment strategies,* JAOA, 2005. Level of evidence: 3
9. ↑ C.S. Braakman, C.S. Hazebroek, I.M.M. van Leeuwen, H.A. van der Meer, Concept praktijkrichtlijn, hoofdpijn, hogeschool Amsterdam fysiotherapie, 2010. Level of evidence: 5
10. ↑ Pfaffenrath and Kaube(1990); Nilsson (1995)
11. ↑ Antonaci F, Sjaastad O. *Cervicogenic headache: a real headache.* Curr Neurol Neurosci Rep. 2011;4:149-155
12. ↑ Haldeman S. Dagenais S. *Choosing a treatment for cervicogenic headache: when? what? how much?.* The Spine journal 2010;10 169-171
13. ↑ 14.0 14.1 14.2 14.3 Becker WJ*. Cervicogenic Headache: Evidence that the neck is a pain generator.* Headache. 2010;4 699-705
14. ↑ 15.00 15.01 15.02 15.03 15.04 15.05 15.06 15.07 15.08 15.09 15.10 15.11 15.12 15.13 15.14 15.15 15.16 15.17 15.18 Jull G, Stanton W. *Predictors of responsiveness to physiotherapy management of cervicogenic headache.* Cephalalgia. 2005;25:101-108.
15. ↑ Haas M, Spegman A, Peterson D, Aickin M, Vavrek D. *Dose response and efficacy of spinal manipulation for chronic cervicogenic headache: a pilot randomized controlled trial.* Spine Journal [serial on the Internet]. (2010, Feb), [cited May 1, 2011]; 10(2): 117-128.
16. ↑ 17.0 17.1 17.2 17.3 Page P, *Cervicogenic headaches: An evidence-led approach to clinical management,* The International Journal of Sports Physical Therapy, Volume 6, Nr 3, September 2011 Level of evidence:1
17. ↑ McDonnell MK et al.*, A Specific Exercise Program and Modification of Postural Alignment for Treatment of Cervicogenic Headache: A Case Report,* J Orthop Sports Phys Ther, Volume 35, Nr 1, January 2005 Level of evidence:3
18. ↑ 19.0 19.1 19.2 19.3 19.4 19.5 Hall T et all*. Clinical Evaluation of Cervicogenic Headache: A Clinical Perspective.* Journal of Manual and Manipulative Therapy. 2008;16:73-80.
19. ↑ Zwart JA. *Neck mobility in different headache disorders.* Headache 1997;37:6–11.
20. ↑ Bovim G. *Cervicogenic headache, migraine, and tension-type headache. Pressure-pain threshold measurements.* Pain 1992;51: 169–73.
21. ↑ Boxem K, Erd M, Brinkhuize T, Patijn J, Kleef M, Zundert J*. Radiofrequency and Pulsed Radiofrequency Treatment of Chronic Pain Syndromes: The Available Evidence.* Pain Practice 2008;8:385-393.
22. ↑ APTA. Interactive Guide to Physical Therapist Practice 2003. http://guidetoptpractice.apta.org/content/1/SEC21.extract

23. ↑ 24.0 24.1 Fritz JM, Brennan GP. *Preliminary Examination of a Proposed Treatment-Based Classification System for Patients Receiving Physical Therapy Interventions for Neck Pain.* Physical Therapy. 2007;87:513-524.
24. ↑ Cleland et al. *Examination of a Clinical Prediction Rule to Identify Patients with Neck Pain Likely to Benefit from Thoracic Spine Thrust Manipulation and a General Cervical Range of Motion Exercise: Muti-Center Randomized Clinical Trial.* Physical Therapy. 2010;90:1239-1253.
25. ↑ Hall T et al. *Efficacy of a C1-C2 Self-sustained Natural Apophyseal Glide (SNAG) in the Management of Cervicogenic Headache* JOSPT 2007;37:100-107.
26. ↑ harrisonvaughanpt. C1-2 Rotatory HVLAT Chin-Hold Technique. Available from: http://www.youtube.com/watch?v=KdFUfVFEb4U [last accessed 24/11/12]
27. ↑ OptimumCareProviders. 1.2 Deep Neck Flexor - Longus Colli Strengthening Level 2. Available from: http://www.youtube.com/watch?v=1smVSuQiQx8 [last accessed 09/03/13]
28. ↑ ReligiosoPT. Supine Thoracic Thrust. Available from: http://www.youtube.com/watch?v=Rj4Y5JGNPZs[last accessed 09/03/13]|}
29. ↑ TherExVids. Cervical Rotation Self Mobilization Using a Strap. Available from: http://www.youtube.com/watch?v=TNb2cLsgc6c[last accessed 09/03/13]|}
30. Gema Bodes-Pardo et al.; *Manual treatment for cervicogenic headache and active trigger point in the sternocleidomastoid muscle: a pilot randomized clinical trial;* Journal of Manipulative and Physiological Therapeutics Volume 36, Number 7; 2013; level of evidence 1B.
31. J. Huber et al.; *Reinvestigation of the dysfunction in neck and shoulder girdle muscles as the reason of cervicogenic headache among o ce workers*; Disability & Rehabilitation; 2013 May; 35(10): 793-802 Level of evidence 1B.
32. De Hertogh W et al. *Diagnostic work-up of an elderly patient with unilateral head and neck pain. A case report.* Manual Therapy. 2013 Dec;18(6):598-601; Level of evidence 4.
33. Rubio-Ochoa, J. et al., 2016. *Physical examination tests for screening and diagnosis of cervicogenic headache: A systematic review.* Manual Therapy, 21, pp.35–40. Level of evidence :1A
34. Fredriksen TA, Sjaastad O: *Cervicogenic headache: current concepts of pathogenesis related to anatomical structure.* Clin Exp Rheumatol 2000, 18(suppl 19):S16–S18. Level of evidence 5.
35.Racicki S, Gerwin S, DiClaudio S, Reinmann S, Donaldson M. *Conservative physical therapy management for the treatment of cervicogenic headache: a systematic review.* J Man Manip Ther (2013)21(2):113–24.10.1179/2042618612Y.0000000025. Level of Evidence 1A (keigoe snoepieeee)
36.Sjaastad O, Bakketeig LS.. *Prevalence of cervicogenic headache: Vågå study of headache epidemiology.* Acta Neurol Scand (2008)117(3) :173–80.10.1111/j. 1600-0404.2007.00962.x Level of Evidence 2B
37.Steven B. Silverman, MD; *Cervicogenic Headache: Interventional, Anesthetic, and Ablative Treatment* 2002, 6:308–314. Level of Evidence 5
38. Eugene Wang; Dajie Wang: *Treatment of Cervicogenic Headache with Cervical Epidural Steroid Injection:* Curr Pain Headache Rep. 2014; 18(9): 442 Level of evidence : 1A
39. Fernández-De-Las-Peñas, C. et al., 2006. *Myofascial trigger points and their relationship to headache clinical parameters in chronic tension-type headache*. *Headache*, 46(8), pp.1264–1272. Level of evidence 1B
40. van Suijlekom H.A. et al., *Quality of life of patients with cervicogenic headache: a comparison with control subjects and patients with migraine or tension-type headache.* Headache. 2003 Nov-Dec;43(10):1034-41. Level of Evidence 2B.